

Protective role of omega 3 on histological status of liver of albino rats affected by energy drinks

Imtiaz Aslam¹, Ammara Rasheed², Farhana Jafri³, Raafea Tafweez⁴, Mahjabeen Muneera⁵

¹Assistant Professor Anatomy, Fatima Jinnah Medical University, Lahore, ²Assistant Professor Anatomy, Nishtar Medical University, Multan,

³Associate Professor Anatomy, Fatima Jinnah Medical University, Lahore, ⁴Professor of Anatomy, King Edward Medical University, Lahore,

⁵Professor of Anatomy, Allama Iqbal Medical College, Lahore

Correspondence to: Dr. Imtiaz Aslam, Email: imtiazibrar2@gmail.com

ABSTRACT

Background: During a clinical visit to the dialysis center, a large number of dialysis patients were seen. Most of them gave history of taking energy drinks. This study was planned to see the toxic effects of energy drinks on the liver. The study was done for a period of one month in the animal house of the postgraduate medical institute, Lahore, on albino rats. Omega 3 was selected as a protective agent against the toxicity of energy drinks on liver parenchyma. The purpose of this study was to evaluate the protective role of omega 3 on the histology of liver parenchyma damaged by an energy drink.

Subjects and methods: A total of 30 male adult albino rats were used in this experimental study. They were divided into three groups with 10 animals in each: Group 1 was treated with distilled water at the dose of 0.5ml/100g of body weight, Group 2 was given an energy drink at the dose of 1.5ml/100g of body weight and Group 3 at the dose of 0.04-0.05ml/100g of omega 3 and 1.5ml/100g of body weight of energy drink. All doses were given for 4 weeks, orally once daily.

Results: Hepatotoxicity was produced by the energy drink, as histological parameters deranged in experimental group 2, which was treated with the energy drink alone. While group 3, which was treated with omega 3 along with energy drink showed the protection of hepatic architecture to some extent by reducing inflammation and nuclear changes to prove the protective role of omega 3.

Conclusion: Energy drink when given at dose of dose was 1.5ml/100gram/body wt. 1.8ml was average dose adjusted on average base for a period of one month causes hepatotoxicity in albino rats. Omega 3 was given as at dose of 0.04-0.05ml/100 gm of body weight/day for a period of one month. It is concluded that 0.04-0.05ml/100mg of b.w/day of Omega 3 offered partial protection to liver against damage by energy drinks.

Keywords:

Energy drink, Omega 3, Hepatotoxicity in rats, Pyknosis, Inflammatory changes

INTRODUCTION

Energy drinks (ED) are the beverages that most of the people use to take extra energy and mood enhancement.¹ More than half of the users of energy drinks are youngsters between 15-35 years of age. They drink for the sake of adventure without the awareness of its side effects. Energy drinks are marketed on the claim to improve energy, to cause weight loss and to increase stamina to attract athletes and students.^{2,3,4}

The main ingredient of ED include caffeine, derivatives of sugar like fructose, glucose and glucuronolactone, ephedrine, guanine and other stimulants derived from taurine, some herbal extracts and vitamin B complex.⁵

Although energy drinks are claimed to be formulated in such a way that each ingredient present in

it is safe for consumption^{6,7} but studies show that their consumption may increase LDL, serum transaminases and blood glucose levels. A very high level of liver glycogen may lead to liver damage and unexpected metabolic damage by increasing lipid peroxidation through raising level of Malonyldialdehyde (MDA)⁸ of poly-unsaturated fatty acids (PUFA). Major types of long chain fatty acids are eicosapentaenoic acid (EPA) and docosahexaenoic acid (DHA). Major source is seafood, small amount are synthesized in body using linolenic acid and naturally occurring fatty acids from plant sources like flaxseed, canola and walnut.¹⁰ Omega 3 has anti-inflammatory, antioxidant and antihypertensive properties.¹¹⁻¹³ Long term use produces favorable effects on parameters related to Alzheimer's disease in animal models.¹⁴ The protective role of omega-3 on liver has been established against toxicity induced by paracetamol, ifosfamide and thioacetamide.¹⁵⁻¹⁷

SUBJECTS AND METHODS

In this experimental study 30 adult albino male rats,

Conflict of Interest: The authors declared no conflict of interest exists.

Citation: Aslam I, Rasheed A, Jafri F, Tafweez R, Muneera M. Protective role of omega 3 on histological status of liver of albino rats affected by energy drinks. J Fatima Jinnah Med Univ. 2021; 15(4):156-160.

DOI: <https://doi.org/10.37018/CSYS3378>

weighing 130-160 grams were taken. They were kept in stainless steel cages under standard controlled conditions of $23 \pm 2^\circ\text{C}$ temperature, $50 \pm 5\%$ humidity and 12 hours' light and day cycles. After initial acclimatization the animals were randomly divided by lottery method into three groups of ten rats each. Each group was labelled with different color. Group 1 was control group and was given distilled water, Group 2 was experimental group administered energy drink (ED) "Red Bull" in a dose of 1.5ml/100g body weight (b.w.). Group 3 was second experimental group and these rats were given both ED and Omega 3. ED was given in a dose of 1.5ml/100g b.w. and 300mg/1000g omega 3 equivalent to 0.04-0.05ml/100gm of body weight. All solutions were administered orally once daily by gavage method for 30 days. All animals were weighed before and at the end of experiment. At the end of the experiment the animals were dissected under chloroform anesthesia and sacrificed on 30th day. Livers removed and fixed in 10% formalin solution to preserve architecture. Tissues processed and prepared for routine histological slides. 3-5 μm thick sections were mounted on slides and stained with hematoxylin and Eosin and with periodic acid Schiff: this stain was used in experiment to differentiate between glycogen storage and vacuolization in hepatocytes. Because glycogen deposit appears as vacuoles on normal histological appearance. Stained slides were observed under light microscope with magnifications of X4, X10 and X40. Hepatotoxic changes were measured by size of nucleus, pyknosis¹⁸ (Absent/mild/moderate/severe) congestion (present/absent) and periportal inflammation (absent/mild/moderate/severe).^{19,20} The quantitative measures like size of nucleus was presented by mean + SD and all qualitative variables (pyknosis, congestion, and inflammation) were presented by frequencies and percentages. ANOVA was applied to find out the significant difference between size of nucleus among three group and fisher exact test was applied to find out association between groups. Nuclear pyknosis, inflammatory changes seen around portal triad and congestion of central vein were observed as quantitative parameters. Data was analyzed by using SPSS version 21. Pearson's Chi-square was applied for association between qualitative data. A p-value of ≤ 0.05 was taken as statistically significant association.

RESULTS

All slides were observed at 10X, 20X and 40X objective lenses. The mean nucleus size was also recorded smallest for the group 2 with value $4.49 \pm 0.28\mu\text{m}$ in

comparison with control with $6.86 \pm 0.25\mu\text{m}$ and protective group with $5.70 \pm 0.22\mu\text{m}$. The overall difference was highly significant with p-value < 0.001 . When compared the difference among groups pair wise, all were also found significant on each instance with p-value < 0.001 . All slides of control group 1 showed normal architecture of liver in form of hexagonal hepatic lobules having central vein with portal triads at periphery. Hepatocytes were arranged as radiating hepatic cords of one or two cell thickness. No periportal inflammation or vascular congestion was seen (Figure 1, and 2).

In group 2, Pyknotic changes as evident by dark staining nuclei were observed. Wide sinusoidal spaces were lined by inflammatory cells (lymphocytes). Central vein showed congestion (Figure 3 and 4). Pyknotic changes were evident by dark staining nuclei (Table 2). The inflammatory changes around portal triad were present in group 2 and 3 while absent in group 1. In group 2, 30% animals had mild and 70% animals had moderate inflammation (Table 4). Whereas congestion was present in 90% animals of group 2 (Table 3).

Group 3 showed preservation of general architecture of hepatic lobules. Mild vacuolar degeneration was present. Binucleated hepatocytes with rounded nuclei containing prominent nucleoli and increased eosinophilia represent the signs of regeneration were also present (Fig 5). Congestion was present in 90% animals of group 2 and 30% of group 3 while absent in all animals of group 1. The group 3 also had significant difference from group 2 with p-value = 0.020 (Table 3). Variation in size of nuclei (Table 1) was present, 60% nuclei showed mild Pyknotic changes, which are less, when compared with group 2 (Figure 3). 30% animals of group 3 showed vascular congestion (Table 3). Periportal inflammation was reduced in group 3, 20% animals had no inflammation while 80% animals showed mild inflammation (Figure 6). The overall difference was found significant with p-value < 0.001 (Table 4).

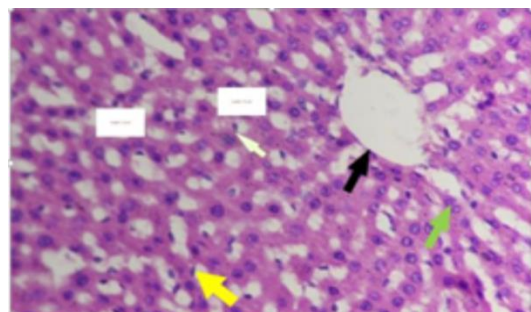


Figure 1.

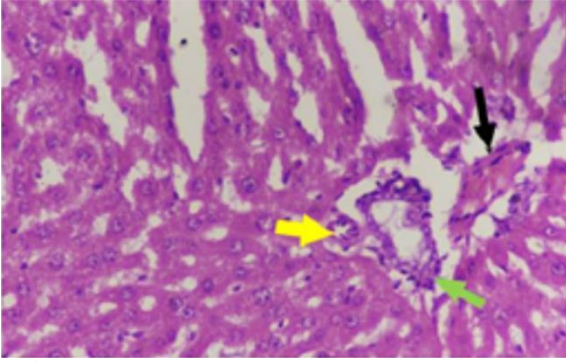


Figure 2.

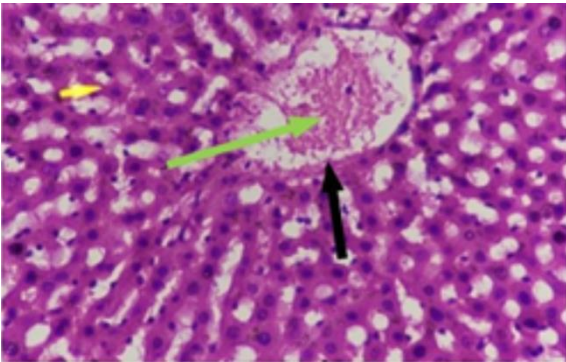


Figure 3.

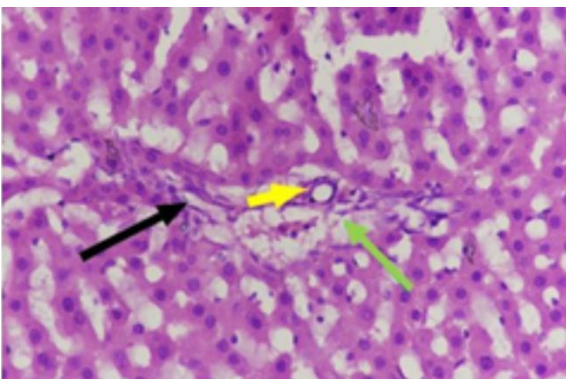


Figure 4.

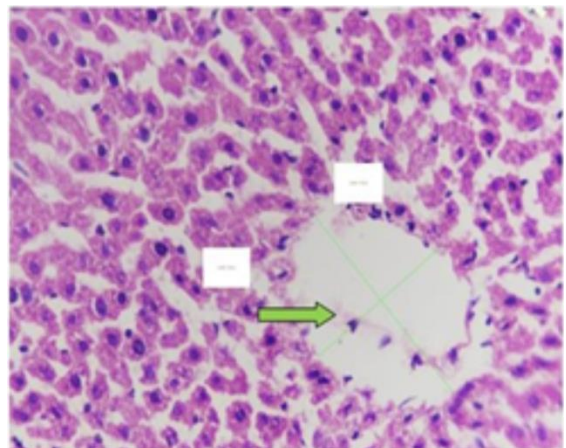


Figure 5.

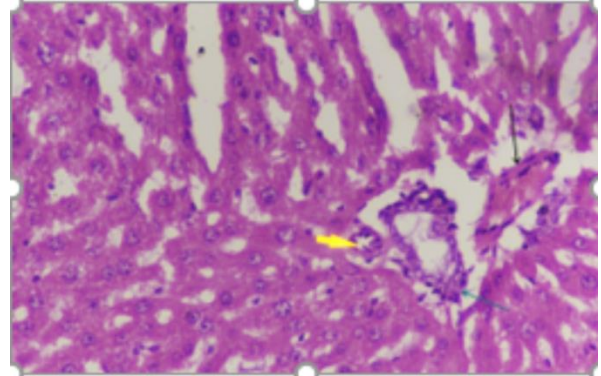


Figure 6.

Table 1. Size of nucleus

Groups	Size of nucleus (Mean ± SD)	p-value
1	6.86 ± 0.22	≤0.005
2	4.49 ± 0.28	
3	5.70 ± 0.25	

Table 2. Pyknosis

Groups	Absent	Mild	Moderate	Severe	p-value
1	10 (100%)	0	0	0	≤0.05
2	0	0	5 (50%)	5 (50%)	
3	0	6 (60%)	4 (40%)	0	

Table 3. Congestion

Groups	Present	Absent	p-value
1	0	0	≤0.05
2	9 (90%)	1 (10%)	
3	3 (30%)	7 (70%)	

Table 4. Inflammation around portal triad

Groups	Absent	Mild	Moderate	Severe	p-value
1	10 (100%)	0	0	0	≤0.05
2	0	3 (30%)	7 (70%)	0	
3	2 (20%)	8 (80%)	0	0	

DISCUSSION

The present study was conducted to confirm the deleterious effects of ED on liver and evaluate the possibility of protective role of simultaneous use of omega 3 against these effects.

Mean nuclear diameter was recorded smallest for the group 2 (Table1) indicating maximum pyknotic changes ranging from moderate to severe extent (Table 2). This pyknosis in group 2 is consistent with studies of Khayat (2012) to show damage of liver tissue by energy drinks.²¹ Present study findings are contradictory with Akende and Banjoko studies where there was no change in nucleus size where the energy drink was given in different dosage and for shorter time period.²² In group 3 the size of nucleus has increased with reduction in pyknotic changes where 60% animals had mild and 40% had moderate pyknosis. This showed protective role of omega 3, consistent with findings of El-Magd et al¹⁷ Parker et al²³, and Asad et al²⁴ and could be due to

antioxidative property of omega 3 consistent with study reported by Moghadamnia in hepatoprotective role of omega 3.²⁵

Congestion was present in 90% animals of group 2 and 30% of group 3 while absent in all animals of group 1 (Table 3). A statistically significant difference was observed between group 2 and group 3. The results of group 2 and 3 collaborate with the findings of Meganathan who studied the protective role of omega 3 against paracetamol poisoning in 2011.²⁶ The results of present study are supported by studies of, Mubarak and Ayoub et al.^{11,21,27} In the present study only 30% animals of group 3 showed mild congestion thus establishing protective role of omega 3. The reason that omega 3 because of its anti-oxidative factor that protect liver tissue to some extent.^{13,28} Blood vessels were less congested in group 3, supported by finding of Moghadamnia²⁶ and Casanova et al.¹³ Energy drinks are associated with infiltration of leucocytes in portal triad and in sinusoidal spaces. These inflammatory cells were found in group 2 and 3 while absent in group 1. 30% animals in group 2 had mild and 70% had moderate inflammation, whereas in group-3, 20% animal had no inflammation while 80% had mild inflammation. So overall the inflammation is reduced in animals of group-3 treated with protection of omega 3. The results collaborate with finding of Khayat et al¹¹ and Latifa et al²⁹, this finding could be attributed by action of high caffeine dose that causes the activation of immune system to overcome infection. Inflammation was found to be reduced in group-3 which supports our hypothesis that omega 3 has succeeded to protect the liver tissue and this is in agreement with previous reports.^{16,24,30}

CONCLUSION

Energy drink when given at dose of 1.5ml/100mg of body weight/per day or a period of one month causes hepatotoxicity in albino rats. Omega 3 was given as a protective agent against toxicity produced by energy drink at dose of 0.04-0.05ml/100gram/body weight/100mg of body weight/day for a period of one month. Hepatoprotective role of omega 3 is evident from modification of histological parameters. At histological level a reduction in inflammation and hepatocellular damage was observed but level of lipid accumulation and congestion remained unaffected. Thus omega 3 is offering partial protection to liver against damage by energy drinks.

REFERENCES

- Ishak WW, Ugochukwu C, Bagot K, Khalili D, Zaky C. Energy drinks: Psychological effects and impact on well-being and quality of life—a literature review. *Innovations in Clinical Neuroscience*. 2012;9(1):25.

- Sara M, Seifert, Judith L, Schaechter, Eugene R, Hershorin, et al. Health effect of energy drinks on children, adolescent, and young adults. *Pediatrics*. 2016;127(3):511-28.
- Jessica L, Reid, McCrory C, Christine M, White, Martineau C, Vanderkooy P, et al. Consumption of caffeinated energy drinks among youth and young adults in Canada. *PMR*. 2014; (5):62-70.
- Larson I, Laska NM, Story M, Sztainer ND. Sports and energy drink consumption are linked to behaviours among young adults. *PHN*. 2014; 18(15):2794-2803.
- Visram S, Hashem K. Energy drinks: What's the evidence? *FRC*. 2016.
- Munteanu C, Utiu I, Corinal L, Rosioru, Lang C. Chronic administration of red bull affect blood parameters in rats. *LIX*. 2014;(2):89-98.
- Crisan M, Munteanu C, Rosioru C, Lang C. Red bull induces biochemical changes in Wistar rat liver. *Ann. Romanian Soc. Cell Biol. Annals of the Romanian Society for Cell Biology*. 2013;18(2):118.
- Femureva CA, Falowiyo MA, Michael A, EPETE, Onuoha CM, Emeka C. Consumption of caffeinated energy drinks induces alteration in lipid profile and hepatic aminotransferases in experimental rats. *JOCPR*. 2015; 7(12):363-69.
- Bronwell L. Groundbreaking Study Reveals New Mechanism Behind Fish Oil's Health Benefits. *Life Extension*. 2012.
- Mohebi-Nejad A, Bikdeli B. Omega-3 supplements and cardiovascular diseases. *Tanaffos*. 2014;13(1):6.
- Ayoub N, ElBeshbeishy R. Impact of energy drink on the structure of stomach and pancreas of albino rat, can omega 3 provide protection. *Plos One*. 2016; 11(2):2.
- Iverson C, Bacong A, Liu S, Baumgartner S, Lundström T, Oscarsson J, et al. Omega-3-carboxylic acids provide efficacious anti-inflammatory activity in models of crystal-mediated inflammation. *Scientific Reports*. 2018; 8(1):1217
- Casanova MA, Medeiros F, Trindade M, Cohen C, Oigman W, Neves MF. Omega-3 fatty acids supplementation improves endothelial function and arterial stiffness in hypertensive patients with hypertriglyceridemia and high cardiovascular risk. *Am J Hypertens*. 2017;11(1):10-9.
- Hooijmans CR, Pasker-de Jong P, de Vries R, Ritskes-Hoitinga M. The effects of long- term omega-3 fatty acid supplementation on cognition and Alzheimer's pathology in animal models of Alzheimer's disease: a systematic review and meta-analysis. *Journal of Alzheimer's Disease*. 2012 ;28(1):191-209
- Hooijmans CR, Pasker-de Jong P, de Vries R, Ritskes-Hoitinga M. The effects of long- term omega-3 fatty acid supplementation on cognition and Alzheimer's pathology in animal models of Alzheimer's disease: a systematic review and meta-analysis. *Journal of Alzheimer's Disease*. 2012;28(1):191-209.
- Meganathan M, Gopal KM, Sasikala P, Mohan J, Gowdhaman N, Balamurugan K, et al. Evaluation of hepatoprotective effect of omega 3-fatty acid against paracetamol induced liver injury in albino rats. *Global J Pharmacol*. 2011;5(1):50-3.
- El-Magd NF, El-Karef A, El-Shishtawy MM, Eissa LA. Hepatoprotective effects of glycyrrhizin and omega-3 fatty acids on Nuclear Factor-kappa B pathway in thioacetamide-induced fibrosis in rats. *Egyptian Journal of Basic and Applied Sciences*. 2015;2(2):65-74.
- Abdel-Dayem MA, Elmarakby AA, Abdel-Aziz AA, Pye C, Said SA, El-Mowafy AM. Valproate-induced liver injury:

- modulation by the omega-3 fatty acid DHA proposes a novel anticonvulsant regimen. *Drugs in R&d*. 2014;14(2):85-94.
19. Kumar V, Abbas AK, Fausto N, Aster JC. Robbins and Cotran Pathological basis of disease. 8th Edn. Saunders Elsevier. City. 2010.
 20. Ishak L, Baptista A, Bianchi L, Callea F, Groottes JD, Gudat F, et al. Histological grading and staging of chronic hepatitis. *J Hepatol* 1995; 22: 696-699.
 21. Khayat L, Sorour J, Alrawi M, Essawy A. Histological, ultrastructural and physiological studies on effects of different kinds of energy drinks on liver of albino rat. *J Am Sci*. 2012; 8(8):688-97.
 22. Akande IS, Banjoko OA. Assessment of biochemical effect of power horse energy drink on hepatic, renal and histological function of Sprague drawley rats. *Annu Res Rev BIOL*. 2011; 1(3):45-56.
 23. Parker HM, Johnson NA, Burdon CA, Cohn JS, O'Connor HT, George J. Omega-3 supplementation and non-alcoholic fatty liver disease: A systematic review and meta- analysis. *Journal of hepatology*. 2012; 56(4):944-51
 24. Asaad HR, Aziz FM. Protective role of omega-3 fish oil against the toxicity of ifosfamide in male rats. *Jordan Journal of Biological Sciences*. 2012;5(1):37-46.
 25. Meganathan M, Gopal KM, Sasikala P, Mohan J, Gowdhaman N, Balamurugan K, et al. Evaluation of hepatoprotective effect of omega 3-fatty acid against paracetamol induced liver injury in albino rats. *Global J Pharmacol*. 2011;5(1):50-3
 26. Meganathan M, Gopal KM, Sasikala P, Mohan J, Gowdhaman N, Balamurugan K, et al. Evaluation of hepatoprotective effect of omega-3 fatty acid against paracetamol induced liver injury in albino rats. *Global J Pharmacol*. 2011;5(1):50-3.
 27. Mubarak R. Effect of energy drink on rats submandibular salivary glands (light and electron microscopy). *J Am Sci*. 2012; 8(1):366-9.
 28. Siscovick DS, Barringer TA, Fretts AM, Wu JH, Lichtenstein AH, Costello RB, et al. Omega-3 polyunsaturated fatty acid (fish oil) supplementation and the prevention of clinical cardiovascular disease: a science advisory from the American Heart Association. *Circulation*. 2017; 135(15):e867-84.
 29. Latifa I, Hayyat K, Amina E, Maissa M, Al Rawy, Jehan M, et al. Comparative study on the effect of energy drinks on haematopoietic system in Wistar albino rats. *JEB*. 2014; 35(1)883-91.
 30. Linecker M, Limani P, Kambakamba P, Kron P, Tschuor C, Calo N, et al. Omega-3 fatty acids protect fatty and lean mouse livers after major hepatectomy. *Ann Surg* 2017;266(2):324-32.