

Surgical Outcomes and OCT RNFL-Based Structure-Function Assessment of Pituitary Macroadenomas after Endoscopic Endonasal Transsphenoidal Surgery

Usman Ahmad¹, Syed Shahzad Hussain Shah¹, Muhammad Irfan¹, Hafiz Muhammad Irfan Razzaq¹, Danish Shafique¹, Laiba Fatima¹, Tehreem Asif¹

¹Punjab Institute of Neurosciences, Lahore General Hospital, Lahore, Pakistan

Correspondence to: Usman Ahmad, Email: usmanschemer644@htomail.com

ABSTRACT

Background: This study assessed the effects of endoscopic endonasal transsphenoidal surgery (EETS) on visual and surgical outcomes in pituitary macroadenoma patients, focusing on tumor resection rates, visual improvement, and postoperative complications.

Methods: This quantitative retrospective study included 30 patients who underwent EETS for pituitary macroadenomas. Preoperative assessments included demographics, tumor size, Knosp grade (MRI), visual acuity (Snellen), visual fields (perimetry), and retinal nerve fiber layer (RNFL) thickness (OCT). At 12 weeks postoperatively, visual tests, RNFL thickness, and contrast-enhanced MRI were repeated to assess resection. Complications such as CSF leak, hemorrhage, infection, and neurological deficits were recorded. Paired t-tests compared pre- and postoperative visual and RNFL outcomes, while chi-square tests analyzed associations between Knosp grade, resection extent, and complications.

Results: Of the 30 patients, 63.3% were male and 36.7% female, with a mean tumor size of 3.8 ± 1.1 cm. Higher Knosp grades were significantly linked to incomplete resection ($p < 0.05$). Complete tumor removal was achieved in 66.7% of cases, while 46.7% experienced postoperative complications—most commonly hemorrhage (20%) and CSF leak (10%). Visual acuity improved significantly ($p < 0.05$), with severe impairment ($\leq 6/60$) decreasing from 23.3% to 6.7% in the right eye and from 26.7% to 6.7% in the left. RNFL thickness also increased significantly, indicating optic nerve recovery.

Conclusion: EETS markedly enhances visual function and optic nerve integrity in pituitary macroadenoma patients. However, higher Knosp grades correlate with incomplete resection and greater complication rates, highlighting the need for careful case selection and surgical planning.

Keywords: Pituitary Neoplasms, Endoscopy, Visual Acuity, Optical Coherence Tomography, Treatment Outcome

INTRODUCTION

Pituitary macroadenomas are benign tumors that arise from the anterior pituitary gland and are among the most prevalent sellar region neoplasms. These tumors, defined as those exceeding 10 mm in diameter, often present with significant clinical symptoms, including progressive visual deterioration due to optic chiasm compression. The impact on visual function varies depending on tumor size, location, and duration of compression, making early intervention crucial.¹

Endoscopic endonasal transsphenoidal surgery (EETS) has revolutionized the management of pituitary macroadenomas, offering a minimally invasive approach with improved visualization and reduced morbidity compared to traditional microscopic surgery. This approach provides superior access to midline skull base lesions while minimizing disruption to surrounding brain structures.² EETS has demonstrated a high success rate in tumor debulking and decompression of the optic apparatus, thereby enhancing visual recovery and improving overall patient outcomes.³

The extent of tumor removal plays a pivotal role in determining surgical success, and Knosp grading has emerged as an essential tool for preoperative assessment. Tumors classified as higher Knosp grades (3 and 4) indicate cavernous sinus invasion, which poses a significant challenge to achieving complete resection.⁴ Studies have shown that subtotal resection, despite being less aggressive, can still yield considerable functional improvement in vision, highlighting the importance of balancing surgical aggressiveness with complication risks.⁵

ARTICLE INFO

Article History: Received: 20 July 2025 | Accepted: 21 January 2026

Conflict of Interest: The authors declared no conflict of interest exists.

Funding: None.

Copyright: © 2025 Ahmad et al. This article is licensed under the Creative Commons Attribution–NonCommercial 4.0 International License (CC BY-NC 4.0), which permits unrestricted non-commercial use, distribution, and reproduction in any medium, provided the original author and source are properly credited.

Citation: Ahmad U, Shah SSH, Irfan M, Razzaq HMI, Shafique D, Fatima L, Asif T. Surgical outcomes and OCT RNFL-based structure-function assessment of pituitary macroadenomas after endoscopic endonasal transsphenoidal surgery. *J Fatima Jinnah Med Univ.* 2025;19(4):190-194.

DOI: <http://doi.org/10.37018/CVDS95637>

Postoperative visual recovery assessment relies on multiple objective measures, including visual acuity testing, perimetry for field defects, and optical coherence tomography (OCT), which provides valuable insights into the integrity of the retinal nerve fiber layer (RNFL). Emerging evidence suggests that preoperative RNFL thinning correlates with poorer postoperative visual prognosis, reinforcing the utility of OCT in predicting long-term visual outcomes in pituitary adenoma patients.⁶ The ability to integrate these diagnostic tools into routine clinical evaluation aids in individualized surgical planning and enhances decision-making.

Despite its advantages, EETS is not without challenges. The risk of complications, particularly cerebrospinal fluid (CSF) leaks and vascular injuries, remains a concern, especially in cases of extensive tumor invasion. Ensuring meticulous intraoperative dural repair and employing advanced reconstruction techniques are key to reducing postoperative morbidity.³ Understanding the correlation between tumor characteristics, resection rates, and complication risk is essential for optimizing patient selection and improving surgical strategies.

This study aims to evaluate the effectiveness of EETS in improving visual outcomes, reducing tumor burden, and minimizing complications. By correlating preoperative characteristics with postoperative results, this research provides clinically relevant data that can aid in refining patient management protocols for pituitary macroadenomas.

SUBJECTS AND METHODS

This was a quantitative retrospective observational study conducted at the Department of Neurosurgery Unit II, Punjab Institute of Neurosciences (PINS), Lahore. Ethical approval was obtained from the Institutional Review Board of Punjab Institute of Neurosciences, Lahore No. 2024/IRB/PINS/Approval/2025 dated 23 January 2025. The study spanned a one-year period from February 2024 to January 2025. Using a non-probability purposive sampling technique, the medical records of 30 patients diagnosed with pituitary macroadenomas who underwent endoscopic endonasal transsphenoidal surgery (EETS) were reviewed.

Data were retrieved from institutional hospital records and digital logs using structured Google Forms. Information collected included demographic details, clinical presentation, tumor size and Knosp grade from preoperative MRI, and ophthalmological evaluations—visual acuity (Snellen chart), visual fields (Humphrey perimetry), and retinal nerve fiber layer (RNFL) thickness measured by optical coherence tomography (OCT). Functional pituitary status (hormone assays) and postoperative MRI findings were also reviewed.

Postoperative outcomes were evaluated based on changes in visual function and RNFL thickness at 12 weeks, extent of tumor resection (gross total vs residual), and the presence of complications such as cerebrospinal fluid (CSF) leak, hemorrhage, infection, and neurological deficits. The patients aged 15–65 years with pituitary macroadenomas (>2 cm) who underwent EETS at PINS between February 2024 and January 2025 were included. However, the patients with pituitary microadenomas (<1 cm), prior pituitary surgery, significant medical comorbidities precluding surgery, or incomplete records were excluded.

Data analysis was performed using SPSS version 26. Quantitative variables were expressed as mean \pm standard deviation. Paired t-tests were used to compare pre- and postoperative visual acuity and RNFL thickness. Chi-square tests assessed associations between Knosp grade, extent of tumor resection, and postoperative complications. A p-value <0.05 was considered statistically significant.

RESULTS

Among the 30 patients included in the study, 63.3% (19/30) were male, and 36.7% (11/30) were female, with a mean age of 46.9 years (range: 30–67 years). The mean tumor size was 3.8 cm (range: 2.1–5.6 cm). Table 1 shows the relationship between individual Knosp grades and tumor resection status. Complete tumor resection was achieved in all patients with Knosp Grades 0 and 1, and in more than half of those with Grade 2. In contrast, Grades 3 and 4 were associated with higher rates of residual tumor. Specifically, residual tumor was present in 5 out of 11 patients with Grade 2, 2 out of 3 patients with Grade 3, and 3 out of 4 patients with Grade 4. These findings underscore a statistically significant inverse relationship between Knosp grade and the likelihood of complete tumor resection ($p < 0.05$), indicating that higher Knosp grades are predictive of incomplete surgical outcomes.

Postoperative complications occurred in 46.7% (14/30) of patients. Hemorrhage was noted in 20.0% (6/30), cerebrospinal fluid (CSF) leaks in 10.0% (3/30), infections in 6.7% (2/30), and new neurological deficits in 3.3% (1/30). The remaining 53.3% (16/30) of patients had an uneventful recovery. A chi-square test confirmed that higher Knosp grades were significantly associated with increased postoperative complications ($p < 0.05$).

Visual outcomes improved significantly following surgery. Figure 1 shows the preoperative and postoperative distribution of visual acuity in both right and left eyes among patients undergoing endoscopic endonasal transsphenoidal surgery for pituitary macroadenomas. Preoperatively, a relatively small proportion of eyes exhibited normal vision (6/6), with only

Table 1: Association between individual Knosp grades and tumor resection

Knosp Grade	Complete Resection (n)	Residual Tumor (n)
Grade 0	3	0
Grade 1	9	0
Grade 2	6	5
Grade 3	1	2
Grade 4	1	3

13.3% (4/30) of right eyes and 10.0% (3/30) of left eyes achieving this benchmark. In contrast, severe visual impairment (defined as $\leq 6/60$ or worse) was present in 23.3% (7/30) of right eyes and 26.7% (8/30) of left eyes. Postoperatively, there was a substantial improvement in visual outcomes. The proportion of eyes with 6/6 vision increased markedly to 50.0% (15/30) in the right eye and 46.7% (14/30) in the left eye. Concurrently, severe visual impairment was significantly reduced to just 6.7% (2/30) in both eyes. These findings underscore the efficacy of surgical decompression in reversing vision loss due to chiasmal compression by macroadenomas. A paired t-test confirmed that the observed improvements were statistically significant ($p < 0.05$), highlighting the positive visual impact of timely surgical intervention.

Figure 2 shows the distribution of retinal nerve fiber layer (RNFL) thickness in right and left eyes before and

after endoscopic endonasal transsphenoidal surgery for pituitary macroadenomas. Preoperatively, the majority of eyes had RNFL thickness values in the lower ranges. Specifically, 26.7% (8/30) of right eyes and 33.3% (10/30) of left eyes were in the 30–50 μm range, while 56.7% (17/30) of right eyes and 40.0% (12/30) of left eyes fell within the 51–80 μm range. These values reflect significant optic nerve fiber thinning likely due to longstanding compression of the optic chiasm by the tumor.

Postoperative assessments demonstrated a marked shift toward higher RNFL thickness values, with 63.3% (19/30) of right eyes and 56.7% (17/30) of left eyes moving into the 81–110 μm range, indicating substantial anatomical recovery of the optic nerve fibers. This improvement is consistent with surgical decompression relieving pressure on the optic apparatus. The change in RNFL thickness was statistically significant ($p < 0.05$), as confirmed by paired t-tests. These findings support the use of optical coherence tomography (OCT) as an objective tool for monitoring optic nerve recovery in patients with visual deficits secondary to pituitary macroadenomas.

Figure 2 shows the distribution of retinal nerve fiber layer (RNFL) thickness in right and left eyes before and

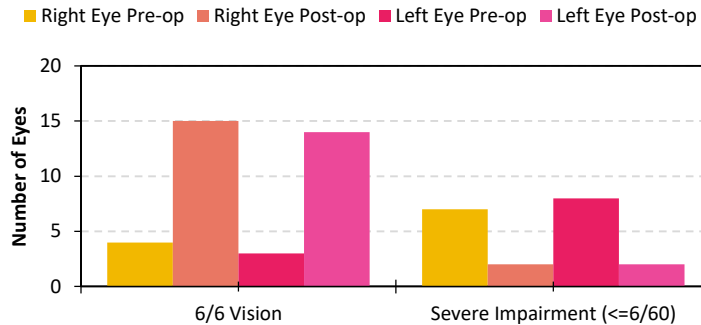


Figure 1: Pre- and postoperative distribution of visual acuity in right and left eyes

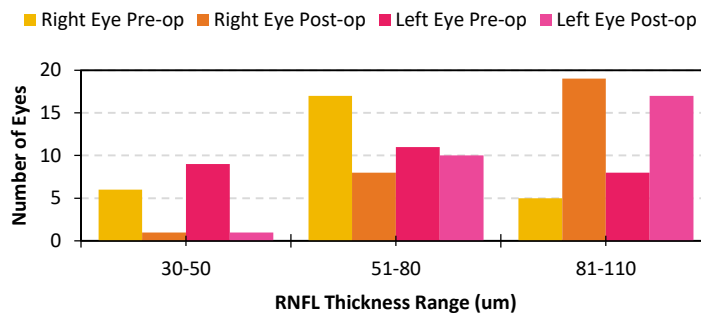


Figure 2: Pre- and postoperative distribution of retinal nerve fiber layer (RNFL) thickness in right and left eyes

Perimetry analysis showed a significant improvement in visual field deficits postoperatively ($p < 0.05$). The mean deviation (MD) score improved from -12.5 dB (± 3.1) preoperatively to -6.8 dB (± 2.4) postoperatively in the right eye and from -13.2 dB (± 2.9) to -7.1 dB (± 2.5) in the left eye. Quadrant-wise assessment indicated better postoperative recovery in the superotemporal and inferonasal quadrants, regions commonly affected by chiasmal compression.

DISCUSSION

This study offers valuable insight into the real-world outcomes of endoscopic endonasal transsphenoidal surgery (EETS) for pituitary macroadenomas in a Pakistani tertiary-care setting. Our results especially the significant improvement in visual acuity (6/6 vision in 50.0% of right eyes and 46.7% of left eyes postoperatively) and corresponding increases in RNFL thickness align closely with both international and regional data.

For instance, a Pakistani case series by Khan et al. reported vision improvement in 87% of patients following EETS, emphasizing the high success rate of this approach in our region.⁶ Another Pakistan-based descriptive study on EETS demonstrated improved visual functions in 89.4% of cases, reinforcing that visual recovery is a consistent outcome across institutions¹³. These findings are consistent with global reports such as those by previous studies which show postoperative visual acuity normalization rates ranging from 45% to 80%.⁶⁻⁸

Our OCT-based analysis of RNFL thickness provides structural confirmation of visual recovery. Preoperative thinning (≤ 80 μm in over 80% of eyes) significantly reversed postoperatively, with $\geq 60\%$ of eyes achieving RNFL ≥ 81 μm in both eyes—a trend matching Indian data from Zhang et al.⁹ and long-term OCT outcomes reported in Korea by Zhou et al.¹⁰ These consistencies affirm OCT's role as a reliable prognostic indicator of visual recovery.

Knosp grade remains a strong predictor of surgical complexity and outcomes. In our study, Grades 3–4 were associated with higher rates of residual tumor and complications (e.g., CSF leaks, hemorrhage), consistent with observations from previous studies who reported increasing surgical risk with cavernous sinus involvement.^{5,7,11} Importantly, though our gross total resection rate (66.7%) is slightly lower than the 70–80% reported in similarly graded cohorts⁷, our center's emphasis on visual protection and risk mitigation likely contributed to favorable functional outcomes.

Our complication rate (46.7%) is higher than the global average of 10–30% but aligns with local data: a Karachi series documented similar CSF leak rates of around 12%, particularly among high-Knosp cases.¹² Greater tumor size and advanced invasion likely

contributed to higher intraoperative and postoperative risk, underscoring the importance of meticulous surgical protocol and robust perioperative care.

Comparison with other minimally invasive techniques is also informative. A comparative study in a neighboring population showed postoperative visual improvement of 86.7% in EETS versus 57.9% in transcranial approaches, with lower complication rates and shorter operative times in EETS cohorts.¹³ This supports our findings and reinforces the strategic value of EETS, especially when visual function is a priority.

Global literature also supports our long-term visual results; diffusion tensor imaging (DTI) studies by Zhang et al. have shown sustained visual field recovery in over 70% of patients after one-year post-EETS.⁹ This aligns with our MD improvements (-12.5 to -6.8 dB right eye) and quadrant-specific recovery.

Based on our findings, endoscopic endonasal transsphenoidal surgery (EETS) should be considered the preferred surgical approach for patients with pituitary macroadenomas, particularly those presenting with visual disturbances. Preoperative evaluations should routinely include high-resolution MRI to assess Knosp grade and optical coherence tomography (OCT) to measure retinal nerve fiber layer (RNFL) thickness, as both parameters were found to be predictive of surgical and visual outcomes. Patients with higher Knosp grades should be thoroughly counseled regarding the increased likelihood of residual tumor and postoperative complications. A multidisciplinary team approach involving neurosurgeons, endocrinologists, and ophthalmologists is essential for optimal management. Postoperative monitoring with OCT and visual field testing at 12 weeks is strongly recommended to assess functional recovery and to guide further therapeutic planning. Institutional adoption of structured perioperative imaging and follow-up protocols will further improve clinical outcomes and patient safety.

This study has several limitations that should be acknowledged. The retrospective design limits control over confounding variables and may introduce selection bias. The relatively small sample size ($n=30$) and single-center setting restrict the generalizability of the findings to broader populations. Furthermore, the follow-up period was limited to 12 weeks, which may not capture the full extent of long-term visual recovery, particularly in cases of chronic compression. OCT imaging was not uniformly available preoperatively for all patients, resulting in incomplete baseline RNFL data. Additionally, the lack of data regarding the duration of visual symptoms, time to diagnosis, and prior medical management limits our ability to account for factors influencing optic nerve recovery. Future studies should adopt prospective, multicenter designs with larger

cohorts and extended follow-up periods to validate and expand upon these findings.

CONCLUSION

Endoscopic endonasal transsphenoidal surgery (EETS) is an effective surgical approach for pituitary macroadenomas, demonstrating significant improvements in visual acuity and retinal nerve fiber layer thickness. Our findings show that higher Knosp grades correlate with increased rates of residual tumor and postoperative complications. These results underscore the utility of EETS not only in achieving tumor resection but also in restoring visual function, particularly when timely intervention is combined with structured radiological and ophthalmologic assessment.

Author Contributions

UA: Conception and design, analysis and interpretation of data, drafting the article, critical revision for important intellectual content, final approval.

SSHS: Conception and design, analysis and interpretation of data.

MR: Analysis and interpretation of data, drafting the article.

HMIR: Acquisition of data, conception and design, analysis and interpretation.

DS: Conception and design, analysis and interpretation of data.

LF: Conception and design, analysis and interpretation of data.

TA: Analysis and interpretation of data, drafting the article.

REFERENCES

1. Luomaranta T, Raappana A, Saarela V, Liinamaa MJ. Factors affecting the visual outcome of pituitary adenoma patients treated with endoscopic transsphenoidal surgery. *World Neurosurg.* 2017;105:422–431.
2. Alsumali A, Cote DJ, Regestein QR, Crocker E, Alzarea A, Zaidi HA, et al. Postoperative vision loss: analysis of 587 patients undergoing endoscopic surgery for pituitary macroadenoma. *J Clin Neurosci.* 2023;107:1–7.
3. Shen M, Chen Z, Shou X, Ma Z, Ye Z, He W, et al. Surgical outcomes and predictors of visual function alterations after transcranial surgery for large-to-giant pituitary adenomas. *World Neurosurg.* 2020;141:e60–e69.
4. Wang MTM, King J, Symons RCA, Stylli SS, Meyer J, Daniell MD, et al. Prognostic utility of optical coherence tomography for long-term visual recovery following pituitary tumor surgery. *Am J Ophthalmol.* 2020;218:247–254.
5. Micko AS, Wöhrer A, Wolfsberger S, Knosp E. Invasion of the cavernous sinus space in pituitary adenomas: endoscopic verification and its correlation with an MRI-based classification. *J Neurosurg.* 2015;122(4):803–811.
6. Paluzzi A, Fernandez-Miranda JC, Stefko TS, Challinor S, Snyderman CH, Gardner PA. Endoscopic endonasal approach for pituitary adenomas: a series of 555 patients. *Pituitary.* 2014;17(4):307–319.
7. Gondim JA, Schops M, de Almeida JP, de Albuquerque LA, Gomes E, Ferraz T, et al. Endoscopic endonasal transsphenoidal surgery: surgical results of 228 pituitary adenomas treated in a pituitary center. *Pituitary.* 2010;13(1):68–77.
8. Ho RW, Huang HM, Ho JT. The influence of pituitary adenoma size on vision and visual outcomes after transsphenoidal adenectomy: a report of 78 cases. *J Korean Neurosurg Soc.* 2015;57(1):23–31.
9. Zhang C, Tong F, Zhou P, Cao M, Zhang S, Zhu H, et al. Acute hemorrhagic apoplectic pituitary adenoma: endoscopic management, surgical outcomes, and complications. *J Craniofac Surg.* 2015;26(5):e431–e435.
10. Yan JL, Chang CN, Chen PY. Endoscopic transsphenoidal surgery for resection of pituitary macroadenoma: a retrospective study. *PLoS One.* 2021;16(8):e0255599.
11. Ceylan S, Koc K, Anik I. Endoscopic endonasal transsphenoidal approach for pituitary adenomas invading the cavernous sinus. *J Neurosurg.* 2010;112(1):99–107.
12. Laws ER, Wong JM, Smith TR, de Los Reyes K, Aglio LS, Thorne AJ, et al. A checklist for endonasal transsphenoidal anterior skull base surgery. *J Neurosurg.* 2016;124(6):1634–1639.
13. Rehman L, Rehman UL, Jabeen R, Rizvi R. Experience of transsphenoidal excision of pituitary adenomas in a tertiary care hospital in Pakistan. *J Pak Med Assoc.* 2024;74(11):1993–1997.